

# We are IntechOpen, the world's leading publisher of Open Access books Built by scientists, for scientists

4,500

Open access books available

118,000

International authors and editors

130M

Downloads

Our authors are among the

154

Countries delivered to

TOP 1%

most cited scientists

12.2%

Contributors from top 500 universities



WEB OF SCIENCE™

Selection of our books indexed in the Book Citation Index  
in Web of Science™ Core Collection (BKCI)

Interested in publishing with us?  
Contact [book.department@intechopen.com](mailto:book.department@intechopen.com)

Numbers displayed above are based on latest data collected.

For more information visit [www.intechopen.com](http://www.intechopen.com)



## Chapter

# Gastrointestinal Manifestations of IgA Vasculitis-Henoch-Schönlein Purpura

*Camelia Cojocariu, Ana Maria Singeap, Stefan Chiriac, Catalin Sfarti, Irina Girleanu, Oana Petrea, Anca Trifan and Carol Stanciu*

## Abstract

Immunoglobulin A vasculitis, formerly called Henoch-Schönlein purpura (HSP), is the most common systemic vasculitis in childhood. It is a small-vessel vasculitis mediated by type III hypersensitivity, manifested as rash accompanied by gastrointestinal (GI) symptoms, arthritis, and nephritis. The etiology of this disease (a leukocytoclastic vasculitis) is still uncertain, but immune complexes of IgA and unidentified antigens seem to have a central pathogenic role. Most often the diagnosis is established after the clinical examination; it is easy at first glance when the clinical presentation includes the classic tetrad of rash (nonthrombocytopenic palpable purpura), arthralgia/arthritis, abdominal pain, and renal manifestations but may be difficult when the gastrointestinal manifestations precede the skin purpuric rash. Gastrointestinal involvement is frequently seen and varies from mild symptoms to severe complications; sometimes the gastrointestinal symptoms (colicky abdominal pain, nausea, vomiting, diarrhea, gastrointestinal bleeding) are the first manifestations of the disease. Immunoglobulin A vasculitis is usually a self-limited disease with a benign course, and the treatment is often symptomatic; in severe cases corticosteroids are necessary.

**Keywords:** Henoch-Schönlein purpura, IgA vasculitis, gastrointestinal involvement

## 1. Introduction

In 1837 Schönlein described a clinical triad manifested as purpuric rash, arthralgias/arthritis, and renal involvement; 1 year later, Henoch related the association of rash, abdominal pain (with bloody diarrhea), and proteinuria; the clinical association of these symptoms was diagnosed as Henoch-Schönlein purpura.

The term Henoch-Schönlein purpura was replaced with immunoglobulin A vasculitis (IgA vasculitis), by the 2012 revised Chapel Hill International Consensus Conference for Nomenclature of Vasculitides [1], based on IgA1-dominant immune deposits affecting small vessels and typically involving the skin, joints, gastrointestinal tract, and kidney.

Henoch-Schönlein purpura (HSP) is a small-vessel vasculitis, characterized by a generalized vascular involvement, usually involving the small vessels of the

skin, the gastrointestinal (GI) tract, the kidneys, and the joints; it is an acute IgA-mediated disorder that rarely may affect the lungs and the central nervous system (CNS) [2]. IgA vasculitis is a multi-system disorder characterized by palpable purpura, arthritis, glomerulonephritis, and gastrointestinal manifestations and is the most common form of systemic vasculitis for children (90% of cases occur in the pediatric patients) [3].

Although a lot of algorithm diagnoses were proposed (The American College of Rheumatology, Michel's criteria, Chapel Hill Consensus Conference, etc.) [1], the diagnostic criteria remain the one published in 2006 [4], revised by the European League Against Rheumatism/Pediatric Rheumatology International Trial Organization/Pediatric Rheumatology European Society (EULAR/PRINTO/PRES); the mandatory criterion is palpable purpura in association with at least one of the following: diffuse abdominal pain, arthritis or arthralgia, renal involvement (hematuria and/or proteinuria), and IgA deposition in biopsy specimen (skin, intestinal tract) [5].

Differential diagnosis includes many diseases with systemic manifestations (cutaneous, articular, gastrointestinal, renal) such as Crohn's disease (no palpable purpura or gastrointestinal bleeding), IgA nephropathy (no palpable purpura), and hypersensitivity vasculitis (absence of IgA deposition) [4].

## **2. Epidemiology**

IgA vasculitis is the most common vasculitis for children; it is usually seen in children between 3 and 10 years old (the age peak is 5–7 years) and very rarely in adults [3, 4]. The annual incidence varies greatly, from 13 to 20/100,000 for children to 0.8–1.8/100,000 for adults [6–8]. Demographic data showed that males are more frequently affected (male-to-female ratio varies from 1.2:1 to 1.8:1) [3, 9].

The diagnosis is more commonly established in winter and spring and rarely in summer [7, 8], and this aspect may be explained by the association of this disease with infection factors, while approximately 50% of IgA cases are preceded by an upper respiratory tract infection [10].

Clinical features and severity of the disease also differ by aging, being more severe in adults than in children [10].

## **3. Pathogenesis**

IgA vasculitis is a small-vessel vasculitis syndrome involving the small vessels of the skin, gastrointestinal tract, kidneys, and joints, consisting of palpable purpura, arthralgia, and gastrointestinal and renal manifestations.

The etiology is still unknown, but precipitating factors such as drug intake and/or upper respiratory tract infections have been associated with the disease development [11]. Although a variety of infectious and chemical triggers are recognized, the underlying cause remains unknown.

In approximately two-thirds of the cases, typical symptoms occur after 7–14 days from an upper respiratory tract infection (previous epidemiological studies have found a seasonal variation of incidence in IgA vasculitis, with more cases occurring in autumn and winter related with upper respiratory tract infection) [4, 11].

Other cases of IgA vasculitis have been associated with several viral infections or vaccinations, foods, drugs, hematological malignancies, and tumors [4].

Henoch-Schönlein purpura (HSP) is mediated by type III hypersensitivity with deposition of IgA immune complex in the walls of vessels.

Histologically, this disease is characterized by leukocytoclastic vasculitis accompanied by IgA immune complexes within affected organs (deposition of IgA and C3 in small-vessel walls, polymorphonuclear leukocyte infiltration around/in small blood vessels, and leukocytoclasia) [11]. The biopsy of the purpuric lesions showed the involvement of small vessels (primarily postcapillary venules) within the papillary dermis and that the predominant cell types within the inflammatory infiltrate are neutrophils and monocytes [12].

Although the pathogenesis of the disease remains unknown, several authors confirmed the implication of abnormal glycosylation of the hinge region of IgA1, elevated levels of IgA anticardiolipin antibodies, and increased levels of transforming growth factor (TGF)-beta in patients with Ig A vasculitis [12, 13].

The diagnosis is often a clinical one (based on the classic symptoms and signs); since there is no disease-specific laboratory abnormality, no specific test available was able to establish the diagnosis.

#### **4. Clinical manifestation**

IgA vasculitis typically has a prodrome (headache, anorexia, fever); after that, a lot of symptoms may develop: rash (especially involving the legs), abdominal pain and vomiting, joint pain (especially involving the knees and ankles), subcutaneous edema, scrotal edema, etc.

The classic tetrad symptoms are rash, arthralgia/arthritis, abdominal pain, and renal manifestations. The clinical diagnosis is easily made in the presence of all these symptoms but may be omitted when the clinical picture is incomplete; in the absence of the classic purpuric rash, the diagnosis of Ig A vasculitis may not be obvious [14, 15].

Purpura and joint pain are usually the main symptoms on admission, but the symptoms may develop over the course of some days to weeks and may vary in their order of presentation.

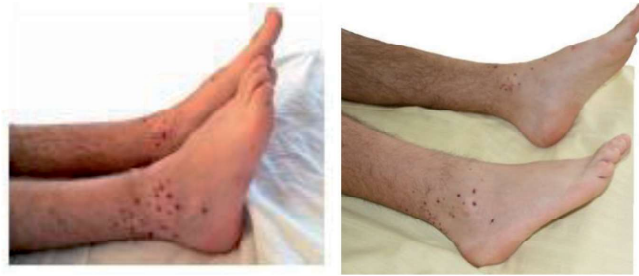The major clinical manifestations are the following:

- Purpura—the appearing symptom in approximately 75% of patients, usually preceding other symptoms
- Arthralgia/arthritis—50–75% of cases
- Abdominal pain—colicky pain in 50% of cases and gastrointestinal bleeding in 20–30% of cases
- Renal disease—20–50% [6, 11, 16–18]

##### **4.1 Skin manifestation**

The skin lesions are the earliest and most common appearance of the disease in the majority of patients (70%) and include palpable nonthrombocytopenic purpura which evolves from erythema to papules and then to non-blanching palpable purpura with petechiae and ecchymosis (**Figure 1**). The rash is the hallmark of the disease and typically appears in crops, with new crops appearing in waves (eruptions usually last an average of 3 weeks).





**Figure 1.**  
*Palpable purpura on both ankles.*

The typical rash is symmetrically distributed and located primarily in gravity-/pressure-dependent areas, such as the feet, ankles, and lower legs in adults; in the case of children, the buttocks, face, trunk, and upper extremities are more affected [19]. In child patients purpura gradually disappears (it can recur and become chronic), but in adults, it may be necrotic or hemorrhagic in 1/3 of cases, and cutaneous exacerbations may be seen for 6 months or longer [20, 21].

#### **4.2 Joint involvement**

Arthralgia or arthritis is present in 2/3 of cases of patients; joint complaints are uncommon as the first symptom, but it is the appearing complaint in approximately 25% of children [21]. The articular manifestations are seen more often in adults than in children; typically involve the hips, knees, and ankles (less commonly the upper extremities); and are symmetrical (as skin lesions) in distribution [4]. The joint involvement is usually transient or migratory, typically oligoarticular and non-deforming. A prominent periarticular swelling and tenderness are usual, without joint effusion, erythema, or warmth. The most frequent symptom is arthralgia, while arthritis is very rare; joint effusions are exceptional [20].

#### **4.3 Renal involvement**

Renal involvement is found in 40–85% of patients (more prevalent in older children and adults), ranging from microscopic hematuria to progressive glomerulonephritis, and is the most serious complication of IgA vasculitis [17, 20]. The most common presentation is hematuria (with/without red blood casts) and mild proteinuria; proteinuria without hematuria is very rare. Renal manifestations usually develop within 4 weeks and never precede the onset of skin lesions. The risk of renal failure is rare in children [22] but may be present in about 30% of adult cases, especially in patients with nephrotic and nephritic syndromes [4]. Nephrotic-range proteinuria, elevated serum creatinine, hypertension, and the coexistence of hematuria and proteinuria are associated with an increased risk of renal failure; 2–5% of patients with renal involvement come to an end-stage renal failure [12, 17].

#### **4.4 Gastrointestinal manifestations**

Gastrointestinal involvement occurs in 50–75% of adult patients—abdominal pain and bloody diarrhea may precede the typical purpuric rash [15, 23]. The digestive symptoms are often present in patients with IgA vasculitis, and although less commonly found in adults, they are more severe and often atypical. The gastrointestinal symptoms vary in intensity, and prudent laparotomy is required to exclude

an acute abdominal condition. Gastrointestinal manifestations range from mild (nausea, vomiting, abdominal pain, paralytic ileus) to severe findings (gastrointestinal bleeding, intussusception, bowel ischemia with secondary necrosis, bowel perforation).

Gastrointestinal symptoms are often the most debilitating manifestations of the disease, and they are much more common in younger patients than in elders [23, 24].

The gastrointestinal manifestations may precede the onset of IgA vasculitis or may develop later in the course of the disease. Typically, gastrointestinal symptoms develop within 8 days from the rash appearance, although longer periods (weeks, even months) have been described. In 10–15% of cases, the gastrointestinal symptoms occur before cutaneous manifestation, making the differential diagnosis of other causes of acute abdomen more difficult [24]. Rarely, gastrointestinal symptoms may appear with no cutaneous purpura at any time [25, 26].

*Abdominal pain* is the most common gastrointestinal symptom, manifested by colicky pain worsened by food (similar to bowel angina), localized to the epigastric and periumbilical regions. The pain is attributed to the involvement of the splanchnic circulation (mesenteric vasculitis) with bowel ischemia and edema of the gastrointestinal tract [4, 23, 27]. Abdominal pain associated with IgAV is caused by submucosal hemorrhage and edema.

Abdominal pain is often associated with diarrhea with gross or occult blood, nausea, vomiting, constipation, and gastrointestinal bleeding (hematemesis or melena).

In most cases, on clinical examination, the abdomen is tender and slightly distended; rarely, it may resemble and be confused with an acute abdomen requiring surgery evaluation (suspicion of perforation, intussusception). Some of these cases, suggesting an acute abdomen, are leading to emergency computed tomography (CT) or unnecessary surgery [4, 23]. Sometimes, particularly in young patients, intense abdominal pain may suggest acute appendicitis, especially when the skin rash is absent. Even in the presence of rash (suggestive in a clinical context for IgA vasculitis) in front of intense abdominal pain, the differential diagnosis of abdominal pain and the exclusion of acute surgical abdomen are mandatory; more, the IgA vasculitis rash may be a nonspecific erythematous or urticarial exanthem or limited to lesions on the buttocks or lower extremities early in the disease course.

*Gastrointestinal bleeding* is another symptom, with an incidence varying between 17.6 and 51% [23]. In most cases, the bleeding is occult (detected as positive stool occult blood); when manifested, the main symptom is melena rather than hematemesis or hematochezia, because the intestinal lesions are usually localized in the small bowel and colon. Gastrointestinal bleeding is usually mild; in rare cases it may be severe, requiring blood transfusion or surgical treatment, even leading to death [4, 23].

Other rare gastrointestinal manifestations, such as *esophageal ulcer*, *pancreatitis*, *pseudomembranous colitis*, *gall bladder involvement*, *intestinal perforation*, and *ischemic vasculitis* may occur [23].

Intussusception is the most common gastrointestinal complication of IgA vasculitis. Edema and hemorrhage can act as a pathological lead point, contributing to the development of intussusception. Intussusception is limited to the small bowel in approximately 60% of cases, in contrast to idiopathic intussusception, which is typically ileocolic. The overall incidence of this complication of IgA vasculitis varies between 2.3 and 3.5%, although some retrospective series reported an incidence of only 0.4 to 0.6% [9, 17]. Children with severe gastrointestinal pain and/or requiring hospitalization are at greater risk.

#### 4.4.1 Imaging evaluation of gastrointestinal manifestation

*Upper gastrointestinal endoscopy* (UGD) is mandatory in patients with gastrointestinal bleeding. UGD is helpful in the diagnosis of IgA vasculitis, especially when gastrointestinal symptoms develop prior to the cutaneous lesions.

The most important part of upper gastrointestinal tract is involved in the second part of the duodenum with endoscopic features including diffuse mucosal redness, petechiae, severe erosive duodenitis, hemorrhagic lesion, and ulcers [28] (**Figure 2**). Purpuric lesions may be seen on an endoscopy, commonly in the descending duodenum, stomach, and colon.

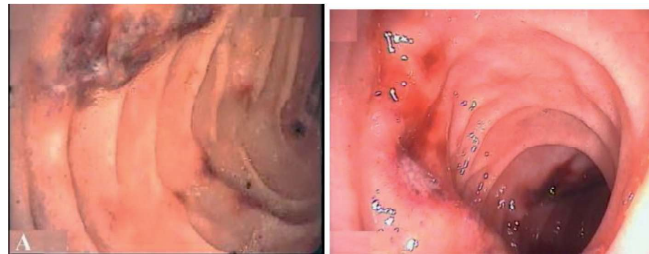The spectrum of upper endoscopic findings is based upon the severity of the vasculitis; usually, irregular, ulcerating, nodular lesions or hematoma-like protrusions are characteristic of IgA vasculitis in the duodenum. The stomach and colon are often involved as well, but the duodenal bulb is rarely affected; the absence of bulbar lesions is important to exclude the cause of the peptic disease hemorrhage [29]. The biopsies of gastrointestinal lesions are commonly performed in patients with or without suspected IgA vasculitis in order to rule out infection, inflammatory bowel disease, and less commonly, vasculitis. In general, vasculitis is not commonly observed in GI biopsies, and the spectrum of findings includes neutrophilic infiltrate within the small bowel and colon, with the duodenum most commonly affected. While the clinical and histologic findings may mimic early inflammatory bowel disease, the presence of predominant small bowel involvement, especially erosive duodenitis, should raise suspicion for IgA vasculitis. Biopsies should be obtained before steroid therapy is initiated, if possible [30].

Resolution of duodenal lesions is spectacular, in accordance with the remission of inflammatory disorders [31] (**Figure 3**).

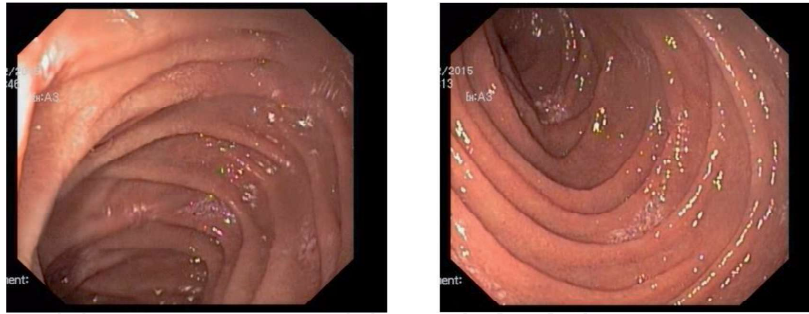*Colonoscopy*: erythema of the mucosa, petechiae, and ulcers are the most common findings [32].

*Computed tomography (CT) imaging*: the hallmarks of IgA vasculitis are multifocal symmetric, circumferential, regular wall thickening and engorgement of mesenteric vessels. Associated findings include free intraperitoneal fluid, ileus of the affected loop, vascular engorgement in the adjoining mesentery, and nonspecific lymphadenopathy [24]. The target sign is not specific; it can be seen in many other conditions such as ischemic bowel disease, inflammatory bowel disease, infectious enterocolitis, radiation enteritis, etc. [19].

In some selected cases, CT angiography can be used to visualize the site of the arterial or venous occlusion; however, a normal angiogram does not rule out the possibility of mesenteric ischemia [3]. Mesenteric vascular engorgement and skip areas are also seen in Crohn's disease, but terminal ileal involvement, stricture, fistula, and abscess would favor Crohn's disease over other conditions [12, 33].



**Figure 2.**  
*Endoscopic appearance of the second part of duodenum: multiple erosions, diffuse redness, submucosal hemorrhage, and small ulcerations.*



**Figure 3.**  
*Endoscopic appearance of the second part of duodenum remission.*

## 5. Conclusion

The diagnosis of IgA vasculitis (HSP) is usually based upon clinical manifestations of the disease, and in patients with an incomplete/unusual presentation, biopsy of the affected organ (e.g., skin or kidney) demonstrating predominantly IgA deposition supports the diagnosis. Although gastrointestinal involvement is frequent, the diagnosis of IgA vasculitis may be difficult when gastrointestinal manifestations occur alone or precede the characteristic skin purpura.

## Author details


Camelia Cojocariu<sup>1,2\*</sup>, Ana Maria Singeap<sup>1,2</sup>, Stefan Chiriac<sup>1,2</sup>, Catalin Sfarti<sup>1,2</sup>,  
Irina Girleanu<sup>1,2</sup>, Oana Petrea<sup>1,2</sup>, Anca Trifan<sup>1,2</sup> and Carol Stanciu<sup>2</sup>

1 University of Medicine and Pharmacy “Gr. T. Popa”, Iasi, Romania

2 “St. Spiridon” Emergency Hospital, Institute of Gastroenterology and Hepatology,  
Iasi, Romania

\*Address all correspondence to: [cameliacojocariu@yahoo.com](mailto:cameliacojocariu@yahoo.com)

## IntechOpen

© 2019 The Author(s). Licensee IntechOpen. This chapter is distributed under the terms of the Creative Commons Attribution License (<http://creativecommons.org/licenses/by/3.0>), which permits unrestricted use, distribution, and reproduction in any medium, provided the original work is properly cited. 



## References

- [1] Jennette JC, Falk RJ, Bacon PA, et al. 2012 Revised International Chapel Hill Consensus Conference Nomenclature of Vasculitides. *Arthritis and Rheumatism*. 2013;**65**(1):1-11
- [2] Szer IS. Henoch-Schönlein purpura. *Current Opinion in Rheumatology*. 1994;**6**(1):25-31
- [3] Piram M, Mahr A. Epidemiology of immunoglobulin A vasculitis (Henoch-Schönlein): Current state of knowledge. *Current Opinion in Rheumatology*. 2013;**25**:171
- [4] Ebert EC. Gastrointestinal manifestation of Henoch Schönlein purpura. *Digestive Diseases and Sciences*. 2008;**53**:2011-2019
- [5] Yang YH, Yu HH, Chiang BL. The diagnosis and classification of Henoch-Schönlein purpura: An updated review. *Autoimmunity Reviews*. 2014;**13**(4-5):355-358
- [6] Gardner-Medwin J, Dolezalova P, Cummins C, Southwood TR. Incidence of Henoch-Schönlein purpura, Kawasaki disease, and rare vasculitides in children of different ethnic origins. *Lancet*. 2002;**360**(9):1197-1202
- [7] Watts RA, Lane S, Scott DG. What is known about the epidemiology of the vasculitides? *Best Practice & Research. Clinical Rheumatology*. 2005;**19**:191-207
- [8] Blanco R, Martínez-Taboada VM, Rodríguez-Valverde V, et al. Henoch-Schönlein purpura in adulthood and childhood: Two different expressions of the same syndrome. *Arthritis and Rheumatism*. 1997;**40**:859
- [9] Trapani S, Micheli A, Grisolia F, et al. Henoch Schonlein purpura in childhood: Epidemiological and clinical analysis of 150 cases over a 5-year period and review of literature. *Seminars in Arthritis and Rheumatism*. 2005;**35**:143
- [10] Schaier M, Freitag J, Dikow R, et al. Henoch-Schönlein purpura in adults is not uncommon in elderly patients with an adverse prognosis. *Clinical Nephrology*. 2011;**76**:49-56
- [11] Calvo Rio V, Loricera J, Mata C, et al. Henoch-Schönlein purpura in northern Spain: Clinical spectrum of the disease in 417 patients from a single center. *Medicine (Baltimore)*. 2014;**93**(2):106-113
- [12] Dedeoglu F, Kim S. IgA Vasculitis (Henoch-Schönlein purpura): Clinical Manifestations and Diagnosis. Available from: <https://www.uptodate.com/contents/iga-vasculitis-henoch-schonlein-purpura-clinical-manifestations-and-diagnosis>
- [13] Lau KK, Wyatt RJ, Moldoveanu Z, et al. Serum levels of galactose-deficient IgA in children with IgA nephropathy and Henoch-Schönlein purpura. *Pediatric Nephrology*. 2007;**22**:2067
- [14] Saulsbury FT. Clinical update: Henoch-Schönlein purpura. *Lancet*. 2007;**369**:976-978
- [15] Cojocariu C, Stanciu C, Ancuta C, Danciu M, Chiriac S, Trifan A. Immunoglobulin A vasculitis complicated with clostridium difficile infection: A rare case report and brief review of the literature. *Journal of Gastrointestinal and Liver Diseases*. 2016;**25**(2):235-238
- [16] Kang Y, Park JS, Ha YJ, et al. Differences in clinical manifestations and outcomes between adult and child patients with Henoch-Schönlein purpura. *Journal of Korean Medical Science*. 2014;**29**:198
- [17] Ghrahani R, Ledika MA, Sapartini G, Setiabudiawan B. Age of onset as



- a risk factor of renal involvement in Henoch-Schönlein purpura. *Asia Pacific Allergy*. 2014;**4**:42
- [18] Peru H, Soylemezoglu O, Bakkaloglu SA, et al. Henoch Schonlein purpura in childhood: Clinical analysis of 254 cases over a 3-year period. *Clinical Rheumatology*. 2008;**27**:1087
- [19] Audemand-Verger A, Pillebout E, Guillevin L, Thervet E, Terrier B. IgA vasculitis (Henoch-Schönlein purpura) in adults: Diagnostic and therapeutic aspects. *Autoimmunity Reviews*. 2015;**14**:579-585
- [20] Pilebout E. Adult Henoch-Schönlein purpura. *Presse Médicale*. 2008;**37**(12):1773-1778
- [21] Thrash B, Patel M, Shah KR, Boland CR, Menter A. Cutaneous manifestations of gastrointestinal disease: Part II. *Journal of the American Academy of Dermatology*. 2013;**68**(2):211.e1-211.e33
- [22] Selewski DT, Ambruzs JM, Appel GB, et al. Clinical characteristics and treatment patterns of children and adults with IgA nephropathy or IgA vasculitis: Findings from the CureGN Study. *Kidney International Reports*. 2018;**3**(6):1373-1384
- [23] Hamzaoui A, Melki W, Harzallah O, et al. Gastrointestinal involvement revealing Henoch Schonlein purpura in adults: Report of three cases and review of the literature. *International Archives of Medicine*. 2011;**4**:31
- [24] Rajalakshmi PP, Srinivasan K. Gastrointestinal manifestations of Henoch-Schönlein purpura: A report of two cases. *World Journal of Radiology*. 2015;**7**(3):66-69
- [25] Nathan K, Gunasekaran TS, Berman JH. Recurrent gastrointestinal Henoch-Schönlein purpura. *Journal of Clinical Gastroenterology*. 1999;**29**:86
- [26] Gunasekaran TS, Berman J, Gonzalez M. Duodenojejunitis: Is it idiopathic or is it Henoch-Schönlein purpura without the purpura? *Journal of Pediatric Gastroenterology and Nutrition*. 2000;**30**:22
- [27] Sohagia BA, Gunturu GS, Tong RT, Hertan LH. Henoch-Schönlein purpura—A case report and review of literature. *Gastroenterology Research and Practice*. 2010;**2010**:7
- [28] Chen XL, Tian H, Li JZ, et al. Paroxysmal drastic abdominal pain with tardive cutaneous lesions presenting in Henoch-Schönlein purpura. *World Journal of Gastroenterology*. 2012;**18**(16):1991-1995
- [29] Dharmesh K, Chodos A, Ahlawat S. Henoch-Schonlein purpura with gastrointestinal involvement in an adult patient. *Gastroenterología y Hepatología*. 2016;**12**(5):321-323
- [30] Louie CY, Gomez AJ, et al. Histologic features of gastrointestinal tract biopsies in IgA vasculitis (Henoch-Schönlein Purpura). *The American Journal of Surgical Pathology*. 2018;**42**(4):529-533
- [31] Rubino C, Paci M, Resti M, Lionetti P, Trapani S. Late relapse of Henoch-Schönlein purpura in an adolescent presenting as severe gastroduodenitis. *Frontiers in Pediatrics*. 2018;**6**:355
- [32] Huang L, Sun L, Lu C, et al. Endoscopy and the management of IgA vasculitis: A clinical analysis of 261 pediatric immunoglobulin A (IgA) vasculitis cases with gastrointestinal involvement and endoscopic examinations of 69 patients. *International Journal of Clinical and Experimental Medicine*. 2019;**12**(2):2035-2041
- [33] Hočevár A, Rotar Z, Ostrovršnik J, et al. Incidence of IgA vasculitis in the adult Slovenian population. *The British Journal of Dermatology*. 2014;**171**:524